Supplementary Figure S1

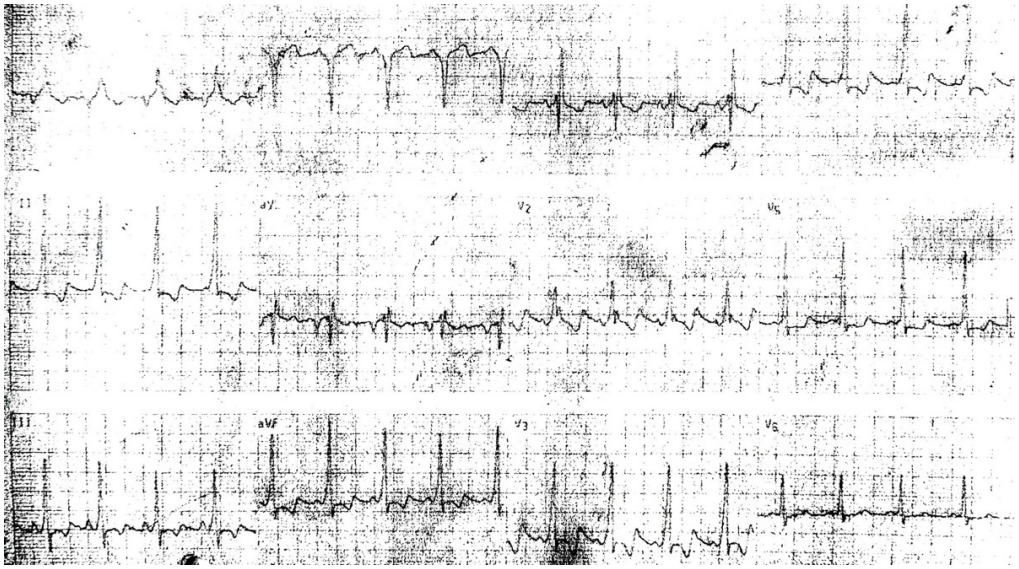

The Case's 1 ECG results at the age of 15 years old, showing the Wolf Parkinson white (WPW) pattern.